

Male-to-Female Transsexualism: Technique, Results and 3-Year Follow-Up in 50 Patients

S. Wagner F. Greco M.R. Hoda A. Inferrera A. Lupo A. Hamza P. Fornara

Clinic of Urology and Kidney Transplantation, Martin Luther University, Halle/Saale, Germany

Key Words

Transsexualism · Gender reassignment, surgical technique · Gender-transforming surgery, functional/cosmetic outcome · Gender-transforming surgery, complications

Abstract

Aim: To evaluate the functional and cosmetic results of male-to-female gender-transforming surgery. **Patients and Methods:** Between May 2001 and April 2008 we performed 50 male-to-female gender-transforming surgeries. All patients had been cross-dressing, living as women, and receiving estrogen and progesterone for at least 12 months, which was sufficient for breast development and atrophy of the testes and prostate to occur. This hormonal therapy was suspended 1 month before the operation. **Results:** The mean operative time was 190 min and the mean depth of the vagina was 10 cm. On follow-up, the most common complication (10%) was shrinkage of the neovagina, which could be corrected by a second surgical intervention. Of the 50 patients, 45 (90%) were satisfied with the esthetic results; 42 patients (84%) reported having regular sexual intercourse, 2 of whom had pain during intercourse. Of the 50 patients, 35 (70%) reported achieving clitoral orgasm. **Conclusion:** Male-to-female gender-transforming surgery can assure satisfactory cosmetic and functional results, with a reduced intra- and postoperative morbidity. Nevertheless the experience of the surgeon and the center remains central to obtaining optimal results.

Copyright © 2010 S. Karger AG, Basel

Introduction

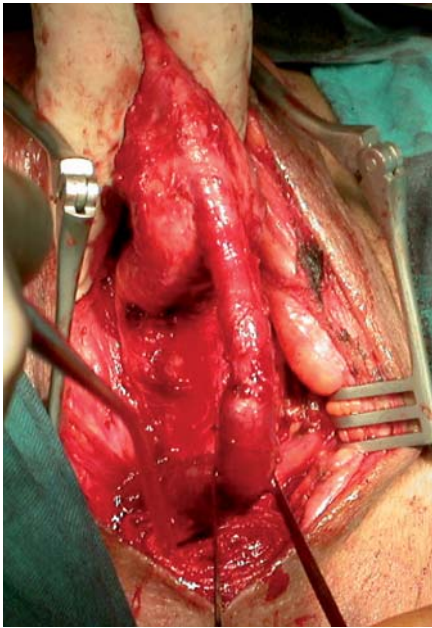
Transsexualism is a disorder of gender identification first described in 1953 by Benjamin [1, 2]. A person in a transsexual condition presents normal genetic, hormonal, and genital characteristics, which are the opposite of their own sexual identification as a male or female. The principal objective of medical treatment is to conform the body to the gender self-perception with a surgical gender operation, which represents the last step in a long process involving psychological, endocrinological, esthetic, and legal procedures [2, 3].

The surgical techniques used in male-to-female gender reassignment have as the principal goal the creation of esthetic and functional external female genitalia, with a profound and compliant vaginal channel. Moreover, the construction of a neoclitoris substantially improves the clinical and functional results [2].

In this study, we describe our technique and report the possible complications and the long-term follow-up of patients with regard to cosmetic and functional results.

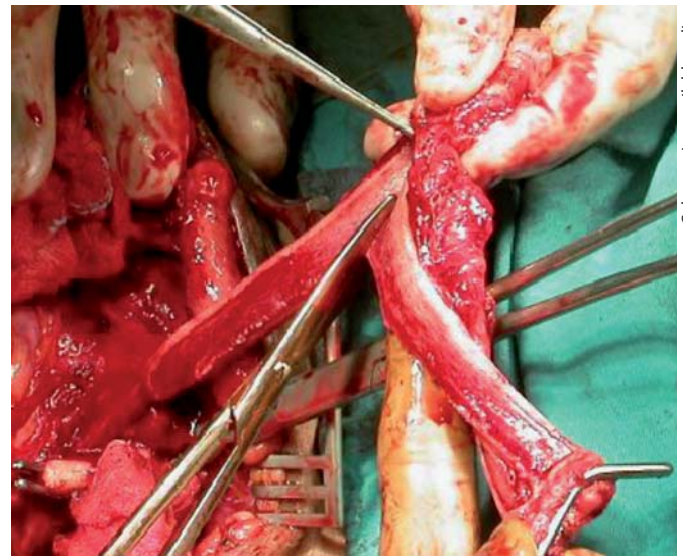
Patients and Methods

In May 2001 we started a prospective study in order to evaluate the cosmetic and functional outcomes associated with our male-to-female transsexual surgery. Between May 2001 and April 2008 we performed 50 male-to-female gender-transforming surgeries. All patients had been cross-dressing, living as women, and



Color version available online

Fig. 1. Preparation of the urethra.



Color version available online

Fig. 2. Preparation of the neurovascular bundle.

receiving estrogen and progesterone for at least 12 months, which was sufficient for breast development and atrophy of the testes and prostate to occur. This hormonal therapy was suspended 1 month before the operation in order to reduce the risk of deep venous thrombosis. All patients had completed a 2-year 'real-life' test and received recommendations from 2 independent psychiatrists regarding their suitability to undergo gender reassignment surgery. The median age of the patients was 38.5 (25–52) years and the mean body mass index was 23. All operations were performed by a single surgeon (P.F.) with extensive surgical experience, which reduced the learning curve effect in this study.

Surgical Technique

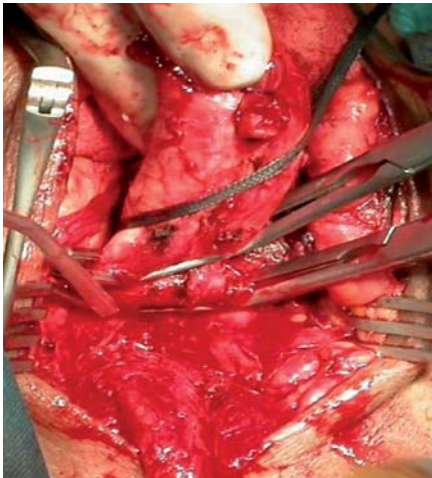
After the usual bilateral orchidectomy with resection of the spermatic cords, the penis is dissected into its anatomical components, with removal of the penile skin and surgical preparation of the urethra and the neurovascular bundle (fig. 1, 2). The corpora cavernosa are removed up to their attachments to the pubic bones (fig. 3). Remnants of the corpora cavernosa (erectile tissue) are destroyed and the tunica albuginea sutured with 2/0 absorbable sutures in order to avoid any postoperative erection (fig. 4). The glans cap is divided into two parts, ventral and dorsal. The sides are de-epithelialized and sutured to obtain a conical shape for the neoclitoris (fig. 2). The ventral half of the glans, which remains attached to the urethra, is used to form the neocervix at the base of the new vagina. The penile skin is invaginated and fixed cranially with two 2/0 absorbable sutures. The urethra is then spatulated, including the bulbar part, and used to create the mucosal part of the neovagina. Space for the new vagina is created in the perineum; two tunnels are made on both sides of the tendinous center; this and the recto-urethral muscle are cut, allowing access to the deep and wide perineal cavity between the urethra, bladder and rectum. Particular care should be taken to avoid injuring the

rectum. The penile skin is invaginated to form the neovagina and is fixed cranially with two 2/0 absorbable sutures to the sacrospinous ligament. Vaginopexy to the sacrospinous ligament is carried out and the neovagina placed deep in the perineal cavity. The remaining part of the base of the penile skin is used to form the labia minora, while the scrotal skin is used to form the labia majora (fig. 5). Peri-vaginal drainage is left for 1 day; the urethral catheter and vaginal tamponade (rolled soft compresses with local antibiotic) are removed 7 days after surgery. A vaginal dilatation system is applied continuously day and night for 10 days. After removal of this system, the patient starts manual dilatation with vibrators for 7 weeks.

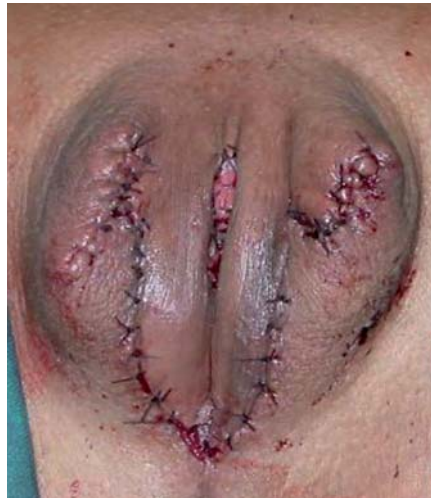Results

The mean operative time was 190 (160–220) min, and the mean depth of the vagina was 10 (6–14) cm. The median hospital stay was 10 (6–14) days.

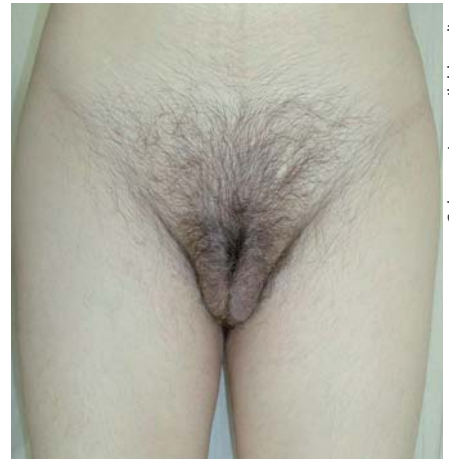Postoperatively 3 patients (6%) presented secondary bleeding, which in 2 patients (4%) required operative revision. The most common complication (10%) in the follow-up was shrinkage of the neovagina, which could be corrected by a second surgical intervention. No postoperative rectocele and no urethrovesical fistulae were found. Only in 2 patients (4%) was a minor bulge in the anterior vaginal wall present, which could easily be resolved by simple excision. Minor complications were subcutaneous hematoma in 3 patients (6%), which did not require a further therapy.



Color version available online



Color version available online



Color version available online

Fig. 3. The corpora cavernosa are removed up to their attachments to the pubic bones.

Fig. 4. Postoperative image of the neovagina.

Fig. 5. Six months after the operation.

At a mean follow-up of 3 years, a questionnaire on the functional results and psychosocial aspects was sent to all patients. Patients who answered the questionnaire noted their degree of satisfaction with the cosmetic results and the depth of the vagina, and their ability for sexual intercourse and achieving orgasm. Of the 50 patients, 45 (90%) were satisfied with the esthetic results; 5 patients (10%) were dissatisfied with the appearance of the labia majora. Concerning the depth of the vagina, 40 patients (80%) were satisfied. Of the 10 patients (20%) who claimed to be unsatisfied, 8 underwent a new operation to augment the vagina. After that, 2 patients were still dissatisfied with the results obtained. Forty-two patients (84%) reported having regular sexual intercourse, of whom 2 admitted to having pain during intercourse. Of the 50 patients, 35 (70%) reported achieving clitoral orgasm.

In the follow-up, the original decision to undergo gender-transforming surgery was confirmed by all but one 24-year-old patient who, 1 month after the operation, regretted his decision and developed strong depression requiring psychological therapy.

Discussion

Transsexualism is a unique condition which is a source of major physical difficulties and creates enormous psychological and emotional conflicts for patients with gender dysphoria. It causes these patients to have extreme psychological pain, societal misunderstanding, and per-

sonal conflict regarding gender identity, and they desire to become as perfect and consonant as possible in body image and physical presentation. Due to improvements in legislation ruling this aspect, in the last years an increasing number of patients have requested male-to-female transsexual surgery [4].

According to the literature [2–13], sex reassignment surgery has proved to be the best solution for primary transsexuals, contributing significantly to psychosocial stability. Pioneers of gender reassignment surgery were Sir Harold Gillies in England and Georges Burou in Casablanca. In the 1950s, they both used invagination of the penile skin sheath to form a vagina. Howard Jones of the Johns Hopkins Institute published the second classic technique using penile and scrotal skin flaps. These two methods form the basis of male-to-female transsexual surgery today [5] and the penile-scrotal skin flap technique is actually considered the state of the art for vaginoplasty in male-to-female transsexuals, whereas other techniques (rectosigmoid flap, local flaps, and isolated skin grafts) should be considered only in secondary cases. Besides, as techniques in vaginoplasty become more refined, more emphasis is being placed on esthetic outcomes by both surgeons and patients [6].

Various methods for neovaginoplasty have been described and can be classified into five categories: pedicled intestinal transplants, penile skin grafts, penile skin flaps, non-genital skin flaps, and non-genital skin grafts. Currently the most favored method is the use of a penile skin flap; this prevents scars at the introitus and, because

it has its own blood circulation, there is less tendency to shrink [4].

In our experience, 50 patients underwent gender reassignment surgery. All patients had been cross-dressing, living as women, and receiving estrogen and progesterone for at least 12 months, which was sufficient for breast development and atrophy of the testes and prostate to occur. The mean operation time was 190 min and the mean depth of the vagina was 10 cm. 90% of the patients were satisfied with the esthetic results and 84% reported having regular sexual intercourse, of whom 35 had clitoral orgasm.

The incidence of surgical complications was comparable to the literature data [4, 7–12]. The most common complication (10%) in the follow-up was shrinkage of the neovagina. In all cases a second surgical correction was necessary to definitively solve the problem. In all patients vaginopexy to the sacrospinous ligament was carried out, reducing the rate of neovaginal prolapse as described in the literature [14].

After 3 years, 49 patients were satisfied and did not regret or had doubts about having undergone sexual reassignment surgery. The only exception was a 24-year-old patient who, 3 days after the operation, regretted his decision. After that, he developed a strong depression

which needed psychological therapy. Two years after surgery, the patient had still not recovered completely and had attempted suicide twice.

We agree with Rehman and Melman [11] that the best age to undergo sexual reassignment surgery is 30 years, an age that enables patients to adjust socially and sexually, increasing the possibility to develop attractiveness and allowing the patients to mature in dealing with new life stresses. Moreover, before undergoing such surgery, it is our opinion that all patients at all ages need deep and intensive psychological examination and must be informed about all the functional and cosmetic risks associated with this operation and, above all, about the impossibility of regretting the decision and returning to their natural gender.

Conclusion

With improvements in surgical technique over the years, male-to-female gender-transforming surgery can assure satisfying cosmetic and functional results, with a reduced intra- and postoperative morbidity. Nevertheless the experience of the surgeon and the center remains a central important aspect for obtaining optimal results.

References

- 1 Benjamin H: Transvestitism and transsexualism. *Int J Sexol* 1953;7:12–14.
- 2 Soli M, Brunocilla E, Bertaccini A, Palmieri F, Barbieri B, Martorana G: Male to female gender reassignment: modified surgical technique for creating the neoclitoris and mons veneris. *J Sex Med* 2008;5:210–216.
- 3 Jarolim L: Surgical conversion of genitalia in transsexual patients. *BJU Int* 2000;85:851–856.
- 4 Krege S, Bex A, Lümmer G, Rübber H: Male-to-female transsexualism: a technique, results and long-term follow-up in 66 patients. *BJU Int* 2001;88:396–402.
- 5 Goddard JC, Vickery RM, Terry TR: Development of feminizing genitoplasty for gender dysphoria. *J Sex Med* 2007;4:981–989.
- 6 Selvaggi G, Ceulemans P, De Cuyper G, et al: Gender identity disorder: general overview and surgical treatment for vaginoplasty in male-to-female transsexuals. *Plast Reconstr Surg* 2005;116:135–145
- 7 Sohn M, Bosinski HA: Gender identity disorders: diagnostic and surgical aspects. *J Sex Med* 2007;4:1193–1207.
- 8 Goddard JC, Vickery RM, Qureshi A, Summerton DJ, Khoosal D, Terry TR: Feminizing genitoplasty in adult transsexuals: early and long-term surgical results. *BJU Int* 2007; 100:607–613.
- 9 Lawrence AA: Factors associated with satisfaction or regret following male-to-female sex reassignment surgery. *Arch Sex Behav* 2003;32:299–315.
- 10 Lawrence AA: Patient-reported complications and functional outcomes of male-to-female sex reassignment surgery. *Arch Sex Behav* 2006;35:717–727.
- 11 Rehman J, Melman A: Formation of neoclitoris from glans penis by reduction glansplasty with preservation of neurovascular bundle in male-to-female gender surgery: functional and cosmetic outcome. *J Urol* 1999;161:200–206.
- 12 Perovic SV, Stanojevic SD, Djordjevic MLJ: Vaginoplasty in male transsexuals using penile skin and a urethral flap. *BJU Int* 2000; 86:843–850.
- 13 Barres BA: Does gender matter? *Nature* 2006;442:133–136.
- 14 Stanojevic DS, Djordjevic ML, Milosevic A, et al: Sacrospinous ligament fixation for neovaginal prolapse prevention in male-to-female surgery. *Urology* 2007;70:767–771.